

MORPHOLOGICAL STUDY OF NUTRIENT FORAMEN OF HUMERUS

Ramkumar¹, J. Senthil Kumar¹, K. Sujatha²

¹Assistant Professor, Department of Anatomy, Govt Stanley Medical college, Chennai, Tamil Nadu, India

²Professor and HOD, Department of Anatomy, Govt Stanley Medical College, Chennai, Tamil Nadu, India

Received : 24/04/2023
Received in revised form : 20/05/2023
Accepted : 02/06/2023

Keywords:

Nutrient foramen, Nutrient canal, Medullary cavity, Humerus.

Corresponding Author:

Dr. J. Senthil Kumar,

Email: senthilkumar8466@gmail.com

DOI: 10.47009/jamp.2023.5.3.279

Source of Support: Nil,

Conflict of Interest: None declared

Int J Acad Med Pharm

2023; 5 (3); 1375-1378



Abstract

Background: The nutrient foramen is small opening(s) present on the surface of the bone which allows nourishment for bone growth and development. The nutrient foramen leads to a nutrient canal which extends into the medullary cavity of the bone. The number and position of nutrient foramen vary in each bone. **Materials and Methods:** In this study, 100 dry adult humerii bone without any anatomical or structural malformation is taken for the study. The presence and absence of the nutrient foramen, its number, position and the direction is recorded, photographed and tabulated. **Result:** In our study, majority of the bone showed single nutrient foramen with 91% and double nutrient foramen with 4%. No triple foramen is recorded. Majority of the nutrient foramen are located on the antero-medial surface with a total of 66% followed by medial border with 25.2%. Out of 95 foramina, 94 foramina (98.94%) were directed away from the growing end of the bone while one specimen (1.05%) was found have horizontal direction **Conclusion:** We highlight the importance of nutrient foramen as it is very important in orthopaedic procedures, treatment and healing of fractures and other pathological conditions. The importance and knowledge of nutrient foramen of the long bone should be taught to I year MBBS students while teaching for better clinical application.

INTRODUCTION

Nutrient foramen (foramina) are small openings present in the diaphysis of a long bone which allows blood vessels and nerves to supply the bone internal structure and helps in active bone growth.^[1] The major source of blood supply to the long bone is derived from nutrient artery supplemented by epiphyseal, metaphyseal and periosteal arteries.^[2-5] The nutrient foramen will lead to the nutrient canal which extends into the medullary cavity of the bone. The nutrient foramen is always directed away from the growing end of the bone.^[6,7] All bones will have one or more nutrient artery which allows continuous nourishment to the bone and plays an important role in active growth of the bone.^[8-10] The nutrient artery is very essential for the bone growth and development. Fracture to the bone may sometime lead to the rupture of the nutrient vessels. This might disrupt the blood supply to the bone thereby poor growth and development.^[11-15] So, knowledge about the nutrient foramen is essential especially for microvascular surgery and orthopaedic surgeries, bone graft procedures and also in medico-legal cases. Knowledge of the nutrient foramen is also very important for

Anatomist for proper teaching the importance of nutrient foramen to the first year MBBS students for clinical application.^[3,7]

Objectives

The study was conducted in the Department of Anatomy, Stanley Medical College, Chennai. The following objectives were studied,

1. Presence or absence of diaphyseal nutrient foramen in each bone.
2. Number of nutrient foramen.
3. Location of the nutrient foramen
4. Direction of the nutrient foramen.

MATERIALS AND METHODS

This study was done in the Anatomy Dissection Hall in Government Stanley Medical College, Chennai. A total of 100 dry adult human humerus bone is taken for the study [Figure 1]. Bones were obtained from the Osteology lab of the Department of Anatomy. Among the 100 specimens, 53 belong to right side and 47 belong to left side. Bones with structural malformations and other deformities were excluded from the study.

Bones with diaphyseal nutrient foramen is studied for its presence, number, location and its direction.

The nutrient foramen is identified for its presence of groove which is usually well-defined. A 24-gauge needle is inserted into the nutrient foramen to check its patency. The presence, number, location and its direction were recorded and tabulated. Magnifying lens is used to identify the foramen. All the foramens noted are tagged, photographed, their landmark identified and documented.



Figure 1: Adult Humerus bones with normal morphology were displayed.

RESULTS

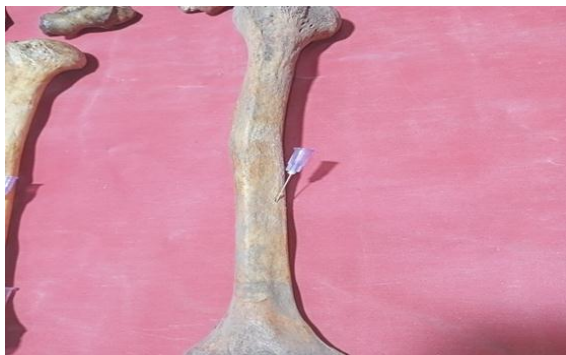

Figure 2: showing single nutrient foramen in the middle of the humerus

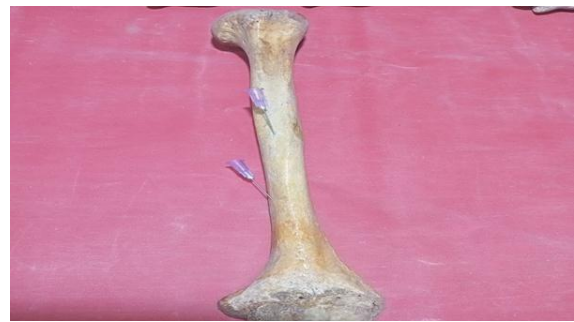

Figure 3: Double nutrient diaphyseal foramen on its anterior and antero-medial surface.

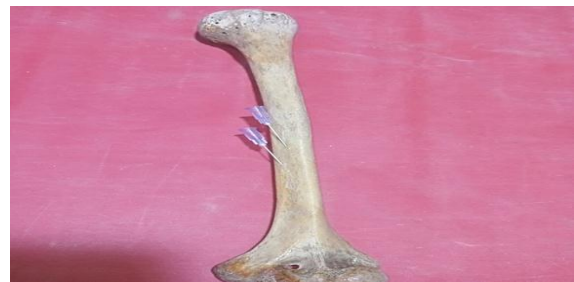

Figure 4: Double nutrient diaphyseal foramen on anterior border

Presence and Number of Foramen

Among the 100-humerus bone, 5 bones (2 from right side and 3 from left side) do not have nutrient foramen on its shaft (5%). Remaining 95% of the humerus showed presence of single or double foramen [Figure 2&3]. 91 bones showed single nutrient foramen (90.5% on right side and 91.4% on left side) and 4 bones showed double nutrient foramen (5.6% on right side and 2.1% on left side). No triple foramen is noted in all 100 specimens.

Direction of nutrient foramen:

Out of 95 nutrient foramina, 94 foramina (98.94%) were directed downward and one nutrient foramen (1.05%) were directed horizontally.

Table 1: showing number of diaphyseal nutrient foramen

| Number of nutrient foramen | Right side (53 specimen) | | Left side (47 specimen) | | Total |
|----------------------------|--------------------------|------|-------------------------|------|-------|
| | Number | % | Number | % | Total |
| Single foramen | 48 | 90.5 | 43 | 91.4 | 91 |
| Double foramen | 3 | 5.6 | 1 | 2.1 | 4 |
| Absent | 2 | 3.7 | 3 | 6.3 | 5 |

Table 2: showing location of nutrient foramen.

| Location of nutrient foramen | Right | | Left | | Both | |
|------------------------------|--------|-------|--------|-------|--------|-------|
| | Number | % | Number | % | Number | % |
| Anterior Border | 3 | 5.6% | 3 | 6.3% | 6 | 6.3% |
| Medial Border | 13 | 24.5% | 11 | 23.4% | 24 | 25.2% |
| Lateral Border | 1 | 1.8% | - | - | 1 | 1% |
| Anteromedial surface | 34 | 64.1% | 29 | 61.7% | 63 | 66.3% |
| Anterolateral surface | - | - | - | - | - | - |
| Posterior surface | - | - | 1 | 2.1% | 1 | 1% |

DISCUSSION

Among the Upper limb, Humerus bone receives the maximum blood supply.^[8,14,15] The nutrient artery to

the humerus comes from branch of brachial artery. It is also supplied by branches of axillary, radial and ulnar arteries. The vasculature of the bone is very important in fracture healing. Since the majority of the humerus has single nutrient foramen, fracture

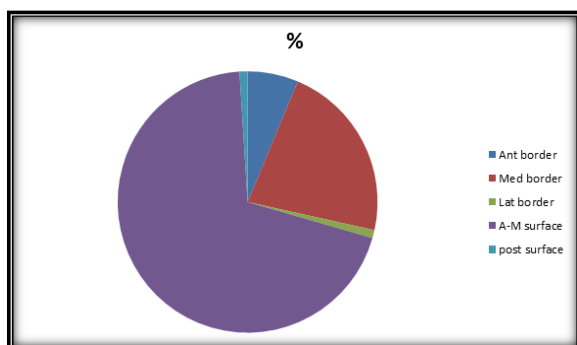
involving the mid-shaft of the humerus possess great danger in fracture healing.^[10]

Number of Foraminas

In the present study, nutrient foramen was present in 95% of the humerus bone (out of 100 specimens) similar to studies done by Khan et al,^[9] (90.67%), Muralimanju et al,^[13] (93.8%), Yaseen et al,^[17] (89%). In the present study, 91 specimen showed single foramen (91%) and 4 specimen (4%) showed double foramen.

| Author | Single foramen | Double foramen | Absent foramen | Triple foramen |
|-------------------------|----------------|----------------|----------------|----------------|
| Mansur et al (2016) | 71.5% | 22% | 2% | 4.5% |
| Khan et al(2014) | 90.7% | 9.34% | - | - |
| Anusha et al(2013) | 72% | 24% | 4% | - |
| Muralimanju et al(2011) | 93.8% | 3.1% | 3% | - |
| Yaseen et al(2014) | 79% | 19% | - | 2% |
| Present study(2023) | 91% | 4% | 5% | - |

In the present study, majority of the nutrient foramen was located in the anterior medial surface (66%) followed by medial border (25%). Majority of the study like Mansur et al,^[12] solanke et al,^[14] Yaseen et al,^[17] showed the nutrient foramen was present more commonly on the antero-medial surface when compared to other surface. According to Grays Anatomy 41st edition, the nutrient foramen is situated a little below its mid-point on the anteromedial surface very close to the medial border.^[15] Ashish Ratwa 2019,^[2] stated that 73.61% of the nutrient foramina were situated in the antero-medial surface comparable to the present study. Similarly other authors like Gopalakrishna et al (70.97%),^[7] Yaseen et al (88.5%),^[17] stated nutrient foramen of the humerus is more commonly present on the antero-medial surface.



Pie chart showing percentage of nutrient foramen in various parts of humerus bone.

Chandan Sintakala,^[5] reported 98.47% of foramen directed downward and 1.53 % directed horizontally. Kumar S et al,^[10] reported 99.54% directed downwards and 0.46% directed horizontally. Present study shows the similar result

with 98.94% of foramen directed downward which is comparable with the previous studies.

An understanding of the anatomical aspect of the nutrient foramen with its location and number is very important for orthopaedic surgeries such as open reduction and internal fixation, bone graft etc.^[16] Understanding of nutrient foramen is also very important for Anatomist for proper teaching the importance of nutrient foramen to first year MBBS students.

CONCLUSION

This study highlights the importance of nutrient foramen in humerus bone. It is important to note that humerus shows single foramen in majority of the specimen which is very important for its vascularity of the entire humerus bone. The vasculature of the humerus should be preserved incase of fracture humerus or other pathological condition for which the landmark and number of the foramen should be known.^[11]

REFERENCES

1. A. Kumar, Sonia Jaiswal, P. K. Sharma, V. Tewari 'The study of nutrient foramen of bones of arm and forearm in adults' 2018 10.24041/ejmr2018.59.
2. Aashish J Rathwa, Sanjay R Chavda "A study on variations of nutrient foramen of humerus with its clinical implications, International Journal of Anatomy and Research 2019, vol 7(1.2):6132-37.
3. Anusha P, Naidu MP. A study on the nutrient foramina of long bones. Jour of Med Sci and Tech. 2013;2(3):150-7.
4. Asharani SK, Ajay Ningaiah 'A study on the Nutrient Foramen of Humerus' International Journal of Anatomy and Research 2016, vol4(3):2706-09
5. Chandan Sintakala, Prabina Manandhar 'Study of Nutrient foramen in humerus' Journal of College of Medical sciences-Nepal, vol16, No4, Oct -Dec 2020.
6. Ehab kamal Ali 'Morphometric And Comparative Study Of Nutrient Foramina Of Femur And Humerus Bones And Its Clinical Importance In Egyptian Population' Sys Rev Pharm 2021;12(3):130-135.
7. Gopalakrishna K, Sreekala MA, Rathna BS. A study on the incidence and direction of nutrient foramina in south Indian humeral diaphysis and their clinical importance. J Med Heal Sci. 2013;3(1):71-6.
8. IB Sing TextBook of Embryology 13th edition pg 145-147
9. Khan AS, Shah Z, Inayat Q. Anatomical variations in diaphyseal nutrient foramina of humerus in cadavers from khyber pakhtunkhwa, pakistan. Khyber Med Univ J. 2014; 6(1):18-21.
10. Kumar S, Kathiresan K, Gowda MST, Nagalaxmi, 'Study of diaphyseal nutrient foraminas in human long bones. Anat Karnataka 2012; 6(2):66-70
11. Kulkarni GS, Limaye R. Nonunion of fractures of long bones. Textbook of Orthopedics and Trauma. 1st edition. New Delhi. Jaypee Brothers medical publishers, 1999;2:1542-4.
12. Mansur DI, Manandhar P, Haque MK, Mehta DK, Duwal S, Timalsina B. A Study on Variations of Nutrient Foramen of Humerus with its Clinical Implications. Kathmandu University Med J. 2016;14(53):78-83
13. Murlimanju BV, Prashanth KU, Prabhu LV, Saralaya VV, Pai MM, Rai R. Morphological and topographical anatomy of nutrient foramina in human upper limb long bones and their surgical importance. Rom J Morphol Embryol. 2011;52(3):859-62

14. Solanke KS, Bhatnagar R, Pokhrel R. The number and position of nutrient foramina in humerus, radius, ulna of human dry bones of indian origin with clinical correlation. *OA Anatomy*. 2014;2(1):1-8.
15. Standing S. *Functional Anatomy of the musculoskeletal system* Grays Anatomy 41st edition . London: Churchill Livingstone Elsevier.2016 pg 806.
16. Suma MP, Sangeetha S, Usha V, Kalpana, Varsha S 'A study of nutrient foramina in the long bones of upper limb' *Anatomica Karnataka* Vol-9(2), page 27-32 2015.
17. Yaseen S, Nitya W, Ravinder M. Morphological and topographical study of nutrient foramina in adult humerii. *Int J Innov Res Sci Eng Technol*. 2014;3(4):7-10.